

ORIGINAL ARTICLE

# Treatment of Skin Papillomas with Topical $\alpha$ -Lactalbumin–Oleic Acid

Lotta Gustafsson, M.Sc., Irene Leijonhufvud, R.N., Annika Aronsson, M.D., Ann-Kristin Mossberg, B.Sc., and Catharina Svanborg, M.D., Ph.D.

## ABSTRACT

### BACKGROUND

We studied the effect on skin papillomas of topical application of a complex of  $\alpha$ -lactalbumin and oleic acid (often referred to as human  $\alpha$ -lactalbumin made lethal to tumor cells [HAMLET]) to establish proof of the principle that  $\alpha$ -lactalbumin–oleic acid kills transformed cells but not healthy, differentiated cells.

### METHODS

Forty patients with cutaneous papillomas that were resistant to conventional treatment were enrolled in a randomized, placebo-controlled, double-blind study, in which  $\alpha$ -lactalbumin–oleic acid or saline placebo was applied daily for three weeks and the change in the volume of each lesion was recorded. After this first phase of the study, 34 patients participated in the second phase, an open-label trial of a three-week course of  $\alpha$ -lactalbumin–oleic acid. Approximately two years after the end of the open-label phase of the study, 38 of the original 40 patients were examined, and long-term follow-up data were obtained.

### RESULTS

In the first phase of the study, the lesion volume was reduced by 75 percent or more in all 20 patients in the  $\alpha$ -lactalbumin–oleic acid group, and in 88 of 92 papillomas; in the placebo group, a similar effect was evident in only 3 of 20 patients (15 of 74 papillomas) ( $P < 0.001$ ). After the patients in the initial placebo group had been treated with  $\alpha$ -lactalbumin–oleic acid in the second phase of the study, a median reduction of 82 percent in lesion volume was observed. At follow-up two years after the end of the second phase, all lesions had completely resolved in 83 percent of the patients treated with  $\alpha$ -lactalbumin–oleic acid, and the time to resolution was shorter in the group originally assigned to receive  $\alpha$ -lactalbumin–oleic acid than among patients originally in the placebo group (2.4 vs. 9.9 months;  $P < 0.01$ ). No adverse reactions were reported, and there was no difference in the outcomes of treatment between immunocompetent and immunosuppressed patients.

### CONCLUSIONS

Treatment with topical  $\alpha$ -lactalbumin–oleic acid has a beneficial and lasting effect on skin papillomas.

From the Institute of Laboratory Medicine, Department of Microbiology, Immunology, and Glycobiology (L.G., I.L., A.-K.M., C.S.), and the Department of Dermatology and Venereology (A.A.), University of Lund, Lund, Sweden. Address reprint requests to Dr. Svanborg at the Institute of Laboratory Medicine, Department of Microbiology, Immunology, and Glycobiology, University of Lund, Sölvegatan 23, S-223 62 Lund, Sweden, or at catharina.svanborg@mig.lu.se.

N Engl J Med 2004;350:2663-72.

Copyright © 2004 Massachusetts Medical Society.

**P**APILLOMAS ARE TUMORS OF THE SKIN and mucosal surfaces formed by keratinocytes that have been transformed by human papillomavirus (HPV).<sup>1,2</sup> Most of the skin lesions remain benign, but the mucosal lesions may be premalignant, and cervical cancer is an important sequela of HPV infection.<sup>3</sup> The HPV viral particle was discovered in 1949,<sup>4</sup> and in 1974 zur Hausen et al. suggested the existence of multiple types of HPV.<sup>5</sup> Skin papillomas are caused by one or more of about 130 different types of HPV<sup>6</sup>; immunosuppressed patients have an increased risk of papillomas<sup>7,8</sup> and may carry multiple HPV types.<sup>9</sup> Current treatments include cryotherapy, curettage, cautery, topical virucidal agents, laser therapy, antimitotic agents, and immunostimulants.<sup>10,11</sup> Vaccines against HPV are being developed, but they are not yet in clinical use.

We identified a molecular complex from human milk that kills transformed cells by a mechanism that resembles apoptosis.<sup>12</sup> Human  $\alpha$ -lactalbumin made lethal to tumor cells (HAMLET) consists of a complex of  $\alpha$ -lactalbumin and oleic acid, which is formed when the protein changes its tertiary conformation and binds oleic acid with a strict stereospecific fit.<sup>13</sup>  $\alpha$ -Lactalbumin-oleic acid is active against a wide range of transformed cell lines *in vitro*, but healthy, differentiated cells are resistant to its effects.<sup>14</sup>

We assessed the activity of  $\alpha$ -lactalbumin-oleic acid on human skin papillomas *in vivo* by means of a randomized, placebo-controlled study, a subsequent open-label study, and a follow-up evaluation after approximately two years.

---

## METHODS

---

### PATIENTS

Forty patients with a history of papillomas that were resistant to conventional treatments were enrolled in a randomized, double-blind, placebo-controlled study comparing topical  $\alpha$ -lactalbumin-oleic acid with placebo (Fig. 1 and Table 1). Thirty-one patients were immunocompetent and had no other illnesses; nine were receiving immunosuppressive drugs after organ transplantation (seven patients) or for systemic lupus erythematosus (one) or Sjögren's syndrome (one). There were 25 female and 15 male patients, with a median age of 21 years (range, 4 to 59). Of the 40 patients, 34 had received conventional therapies: 33 (82 per-

cent) had received salicylic acid, 26 (65 percent) cryotherapy, and 5 (12 percent) laser therapy. Diagnosis was based on visual inspection by an experienced dermatologist. The 40 patients had 166 papillomas, which were nodular or flat and located on the hands (including 3 on the forearms), or feet. Most patients had several lesions (median, 4; range, 1 to 9). The patients were allowed to use conventional therapy one month after the end of the open-label treatment, if they desired. The study was approved by the Medical Ethics Committee of Lund, Sweden. Written informed consent was obtained from all patients.

### PREPARATION OF $\alpha$ -LACTALBUMIN-OLEIC ACID

$\alpha$ -Lactalbumin was purified from human milk whey by ammonium sulfate precipitation, followed by phenyl-Sepharose chromatography.<sup>15</sup> Excess milk from the hospital milk bank that met the stringent criteria for feeding premature babies was used.  $\alpha$ -Lactalbumin-oleic acid was generated from native  $\alpha$ -lactalbumin on an oleic acid-conditioned ion-exchange chromatography column, as described previously.<sup>13</sup> The eluted fractions were dialyzed against distilled water, lyophilized, and stored at  $-20^{\circ}\text{C}$ .  $\alpha$ -Lactalbumin-oleic acid forms a clear solution when dissolved in 0.9 percent saline. For testing, the  $\alpha$ -lactalbumin-oleic acid solution was prepared under sterile conditions and dispensed into opalescent bottles, as was the 0.9 percent saline placebo. Bottles were marked with the randomization code, which also served as the patient identification number, and stored at  $4^{\circ}\text{C}$ . Plastic vials containing  $\alpha$ -lactalbumin-oleic acid or placebo were delivered to the patients by staff members who were not involved in the randomization, dispensation, or evaluation procedures.

### STUDY DESIGN

In the first phase of the study, patients were randomly assigned to receive topical  $\alpha$ -lactalbumin-oleic acid or placebo for three weeks (Fig. 1). On day 1, a drop of  $\alpha$ -lactalbumin-oleic acid (0.7 mM in 0.9 percent saline) or saline placebo was applied to each lesion by the investigator; the lesion was covered with a hydrocolloid dressing (Comfeel, Coloplast) fastened with Micropore tape (3M Health Care). Thereafter, the patients followed the same procedure at home once a day and received a new coded bottle (containing either  $\alpha$ -lactalbumin-oleic acid or placebo) weekly in the clinic.

The papillomas were inspected, measured, and photographed at enrollment, weekly during the three-week treatment period, and one month and two months after the completion of treatment. The width, length, and height of each lesion were measured, with use of a slide caliper, and the volume of each papilloma was calculated.

The randomization code was broken one month after all patients had completed three weeks of the randomly assigned treatment. It was then clear, on the basis of estimates made by the investigators, that  $\alpha$ -lactalbumin-oleic acid was superior to placebo. For this reason, patients in both groups were offered three weeks of open-label treatment with  $\alpha$ -lactalbumin-oleic acid according to the protocol used in the first, randomized phase of the study (Fig. 1). The patients in the initial  $\alpha$ -lactalbumin-oleic acid group were included in the second phase of the study, since the optimal duration of treatment was unknown and some had partial relapses after the discontinuation of  $\alpha$ -lactalbumin-oleic acid. The patients participating in the second phase did not know whether they had received  $\alpha$ -lactalbumin-oleic acid or placebo during the first treatment period. One month after the end of open-label treatment with  $\alpha$ -lactalbumin-oleic acid, the patients were allowed to use conventional treatment if they wished it.

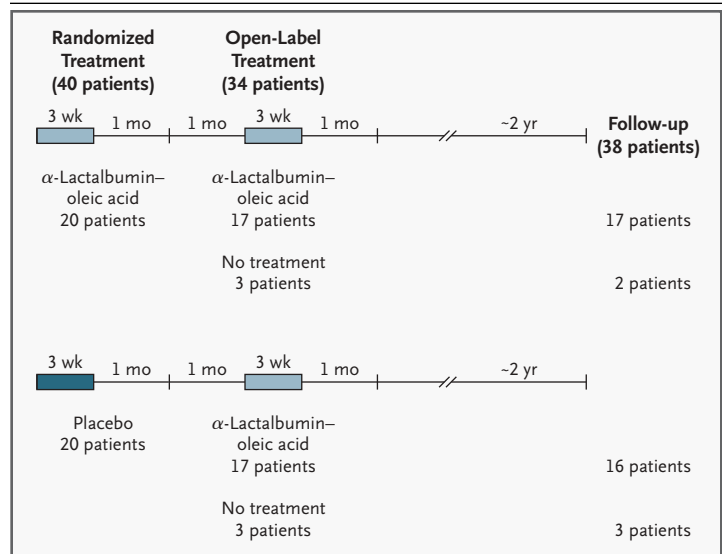
A long-term follow-up investigation was performed approximately 2 years (mean, 2.3 years; range, 1.8 to 2.8) after the completion of the second (open-label) treatment period. Thirty-eight of the original 40 patients were seen in the clinic, the sites of treated lesions and possible new lesions were inspected, and the patients were interviewed about the length of time to the resolution of their lesions, about potential other treatment they had received for papillomas, and about any other illness or treatment in the intervening period. Two patients were lost to follow-up.

**EVALUATION OF POSSIBLE SIDE EFFECTS**

During the first and second phases of treatment and at the follow-up examination, patients were interviewed regarding symptoms in the lesions or the skin adjacent to the treated lesions. The skin surrounding the treated lesions was inspected.

**STATISTICAL ANALYSIS**

Groups were compared with use of the two-sided Student's t-test and the chi-square test with Yates' correction and 1 degree of freedom.



**Figure 1. Study Design.**

In the first phase of the study, 40 patients were randomly assigned to receive either  $\alpha$ -lactalbumin-oleic acid (0.7 mM in 0.9 percent saline) or placebo (0.9 percent saline) for three weeks in double-blind fashion and were evaluated immediately and one month after the completion of treatment. After an additional month, most patients were given three weeks of open-label treatment with  $\alpha$ -lactalbumin-oleic acid. The 34 patients who entered this second phase of the study were followed for one month. A long-term follow-up study, involving 38 of the original 40 patients, was performed approximately two years later.

**Table 1. Baseline Characteristics of the Patients, According to Treatment Group.**

Characteristic	$\alpha$ -Lactalbumin-Oleic Acid (N=20)	Placebo (N=20)
Age (yr)		
Median	17	23
Range	4-59	6-58
Sex (no.)		
Male	6	9
Female	14	11
Immunologic status (no.)		
Immunocompetent	16	15
Immunosuppressed	4	5
Type of lesion (no.)		
Nodular	79	62
Flat	13	12
Location of lesion (no.)		
Hands	68*	49
Feet	24	25
Mean volume of lesions (mm <sup>3</sup> ) †	109	65
Total no. of lesions	92	74

\* Three of the 68 lesions classified as on the hands were located on the forearm.  
 † The volume is of all lesions in all the patients in the group.

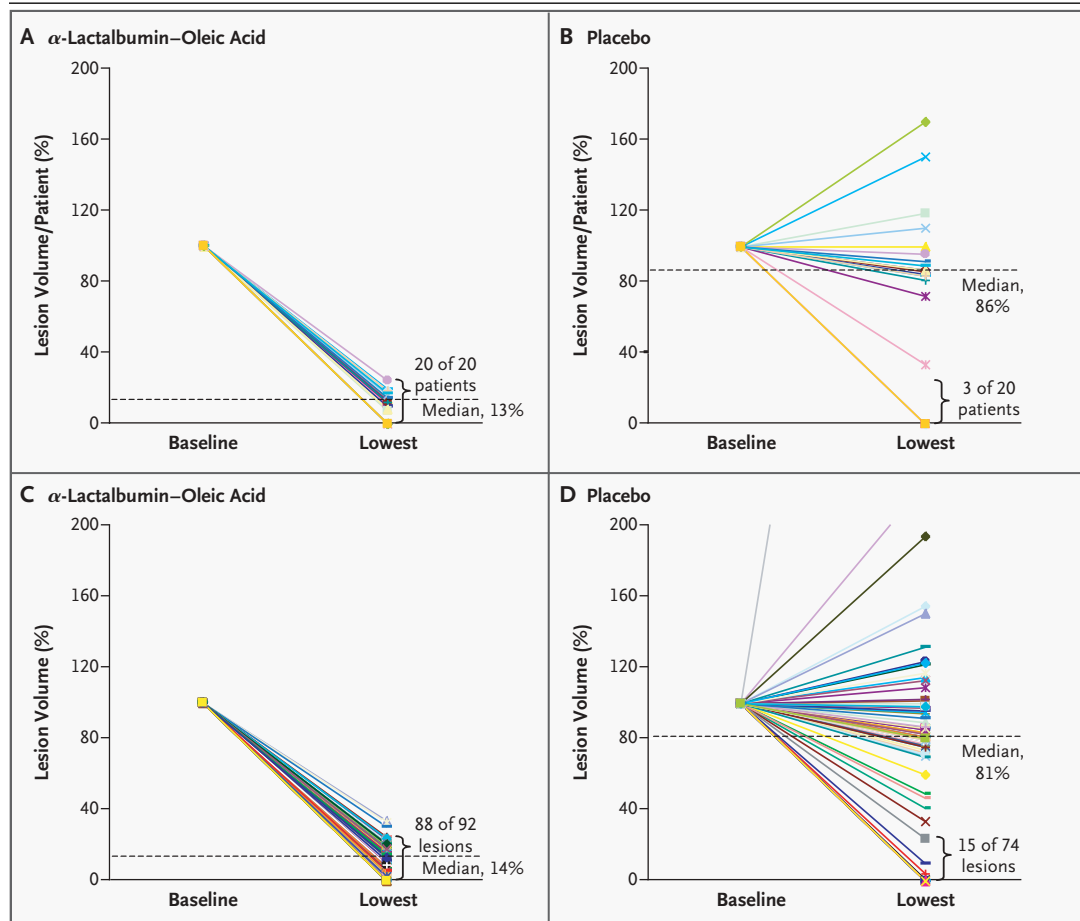
RESULTS

**RANDOMIZED TREATMENT**

Topical application of  $\alpha$ -lactalbumin–oleic acid during the first phase of the study decreased the volume of skin papillomas, as compared with placebo (Fig. 2 and Table 2). The effect of treatment was evaluated on the basis of the lowest recorded lesion volume within one month after the end of the three-week treatment period. There was a decrease in the total lesion volume in all 20 patients treated with  $\alpha$ -lactalbumin–oleic acid; the median remaining volume was 14 percent of the original volume (range, 0 to 33 percent). A decrease in volume of 75 percent or more was recorded in all 20 patients and in 96 percent of their lesions (88 of

92;  $P < 0.001$  as compared with placebo). Resolution of one or more lesions was recorded in 45 percent of the patients (9 of 20), and in 21 percent of their lesions (19 of 92;  $P$  not significant). In the placebo group, the median remaining lesion volume was 81 percent of the original volume (range, 0 to 740 percent), and a decrease of 75 percent or more was recorded in 15 percent of the patients (3 of 20) and in 20 percent of their lesions (15 of 74). Resolution of one or more lesions was observed in 15 percent of the patients (3 of 20) and in 15 percent of the lesions (11 of 74) (Table 2).

The effect of  $\alpha$ -lactalbumin–oleic acid was independent of the sex of the patient and the location and characteristics of the lesions (data not shown).  $\alpha$ -Lactalbumin–oleic acid significantly decreased



**Figure 2. Effects of  $\alpha$ -Lactalbumin–Oleic Acid and Placebo in the First Phase of the Study.**

Panels A and B show the initial average volume of each patient's lesions (set at 100 percent) and the lowest recorded volume after three weeks of randomly assigned treatment. Panels C and D show the same data for each lesion. The dotted lines indicate the median lowest volume as a percentage of the baseline volume, and braces show the proportion of patients or lesions with a reduction of 75 percent or more in lesion volume.

the volume of 96 percent of nodular lesions (76 of 79 lesions;  $P < 0.001$  as compared with placebo), and 24 percent of such lesions (19 of 79) resolved; it significantly decreased the volume of 92 percent of flat lesions (12 of 13;  $P < 0.05$  as compared with placebo), but none resolved. Among lesions on the hands, 97 percent (66 of 68) decreased significantly in volume ( $P < 0.001$ ), and 24 percent (16 of 68) resolved. Similarly, 92 percent of lesions on the feet decreased significantly in volume (22 of 24;  $P < 0.001$ ), and 12 percent (3 of 24) resolved.

#### OPEN-LABEL TREATMENT

All participants in the placebo-controlled study were invited to enter a three-week open-label trial of  $\alpha$ -lactalbumin-oleic acid, starting two months after the first phase of the study (Fig. 1). Treatment again lasted three weeks, owing to a limited supply of  $\alpha$ -lactalbumin-oleic acid. As Figure 3 shows, there was a clear decline in the volume of lesions in the group that had previously received placebo (Fig. 3A and 3C); a further improvement occurred in the  $\alpha$ -lactalbumin-oleic acid group (Fig. 3B and

3D). A decrease of 75 percent or more in lesion volume occurred in 87 percent (58 of 67) of the patients who received  $\alpha$ -lactalbumin-oleic acid during the first and second phases of treatment and in 61 percent (35 of 57) of those who received  $\alpha$ -lactalbumin-oleic acid only during the second phase ( $P < 0.01$ ) (Table 2).

#### LONG-TERM FOLLOW-UP

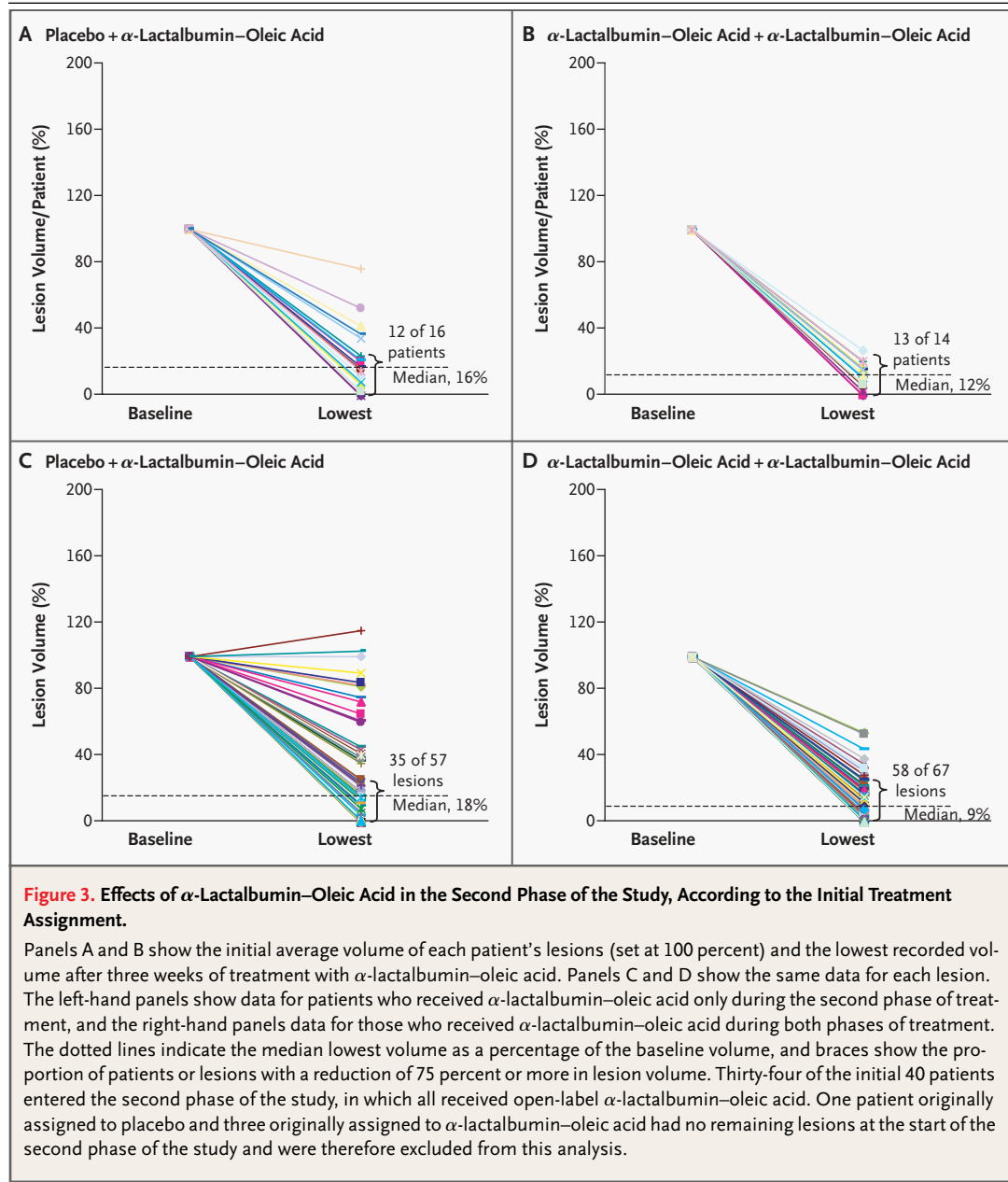
Thirty-eight patients were available for the long-term follow-up evaluation, conducted a mean of 2.3 years (range, 1.8 to 2.8) after the end of the open-label phase of the study. The outcome is summarized in Table 3 and Figure 4. Of the 38 patients, 32 were completely free of papillomas; 3 of these patients had received only placebo. In the 6 patients with remaining papillomas, 47 percent of their papillomas (16 of 34) had completely resolved.

Among the 21 patients who had not used any further treatment after completion of the open-label treatment with  $\alpha$ -lactalbumin-oleic acid, 17 had no recurrences. The lesions disappeared more rap-

**Table 2. Outcomes of Randomized and Open-Label Treatment, According to Randomly Assigned Study Group.\***

Outcome	$\alpha$ -Lactalbumin- Oleic Acid	Placebo	P Value
<b>Randomized treatment</b>			
Lesion volume after treatment (% of baseline)			
Median	14	81	
Range	0–33	0–740	
$\geq 75\%$ Reduction in lesion volume			
Patients (no./total no.)	20/20	3/20	$< 0.001$
Lesions (no./total no.)	88/92	15/74	$< 0.001$
Resolution of lesions			
Patients with $\geq 1$ lesion resolved (no./total no.)	9/20	3/20	NS
Lesions (no./total no.)	19/92	11/74	NS
<b>Open-label treatment with <math>\alpha</math>-lactalbumin-oleic acid</b>			
Lesion volume after treatment (% of baseline)			
Median	9	18	
Range	0–54	0–116	
$\geq 75\%$ Reduction in lesion volume			
Patients (no./total no.)	13/14	12/16	NS
Lesions (no./total no.)	58/67	35/57	$< 0.01$
Resolution of lesions			
Patients with $\geq 1$ lesion resolved (no./total no.)	5/14	5/16	NS
Lesions (no./total no.)	13/67	8/57	NS

\* In the placebo-controlled study, 20 patients were randomly assigned to receive  $\alpha$ -lactalbumin-oleic acid or placebo for three weeks. Subsequently, 17 patients in each group received open-label  $\alpha$ -lactalbumin-oleic acid for three weeks. One patient originally assigned to placebo and three patients originally assigned to  $\alpha$ -lactalbumin-oleic acid had no remaining lesions at the start of the open-label phase of the study and were therefore excluded from the analysis of the open-label phase. The volume of lesions is of all lesions in all patients in the group. NS denotes not significant.



idly in the patients who had received  $\alpha$ -lactalbumin–oleic acid during the first phase of the study (mean time to resolution, 2.4 months) than in the patients who received placebo followed by  $\alpha$ -lactalbumin–oleic acid (mean, 9.9 months;  $P < 0.01$ ) (Table 3).

Seventeen patients had received conventional therapy after completing open-label treatment with  $\alpha$ -lactalbumin–oleic acid. On follow-up, 15 of them had complete resolution of all treated lesions and no evidence of recurrences or new lesions. At

the end of the open-label treatment, the lesion volumes in this group were similar to those in the group that did not choose conventional treatment; thus, the patients who chose conventional treatment did not represent a subgroup with potential resistance to the effects of  $\alpha$ -lactalbumin–oleic acid.

**CHARACTERISTICS OF THE LESIONS**

Figure 5 shows representative morphologic changes in papillomas treated with  $\alpha$ -lactalbumin–oleic

**Table 3. Two-Year Follow-up Data on 38 Patients.**

Randomized Treatment	Open-Label Treatment	Patients <i>no.</i>	Complete Resolution <i>no. (%)</i>	Resolution of $\geq 1$ Lesion <i>no. (%)</i>	Time to Complete Resolution*
					<i>mo</i>
$\alpha$ -Lactalbumin-oleic acid	$\alpha$ -Lactalbumin-oleic acid	17†	13 (76)‡	15 (88)	2.4
$\alpha$ -Lactalbumin-oleic acid	—	2†	2 (100)‡	2 (100)	0
Placebo	$\alpha$ -Lactalbumin-oleic acid	16†	14 (88)‡	16 (100)	9.9
Placebo	—	3	3 (100)	3 (100)	3.4

\* These estimates are based on data on the 21 patients who did not receive conventional therapy after the open-label phase of the study. The time to complete resolution is the number of months from the end of the second phase of treatment; 0 denotes lesions that were completely resolved at the end of the second phase.

† These patients received  $\alpha$ -lactalbumin-oleic acid either during the first phase or during both the first and second phases.

‡ These patients had complete resolution of all lesions.

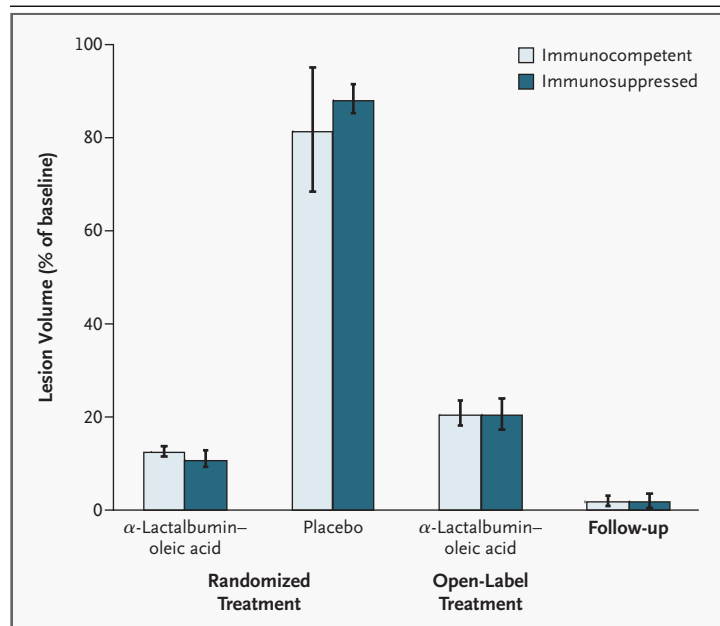
acid. Most of the lesions gradually lost volume during the treatment period, leaving traces with markedly changed morphologic features. With time, the lesions disappeared. No reactions were observed in areas of skin around the papillomas that were exposed to the  $\alpha$ -lactalbumin-oleic acid solution. The patients reported no symptoms in healthy skin, but some reported a prickling sensation in the lesion.

#### EFFECTS OF IMMUNE STATUS

The effect of  $\alpha$ -lactalbumin-oleic acid was probably independent of the immune status of the patients, although the group with immunosuppression was small (Fig. 4). The four immunosuppressed patients who received  $\alpha$ -lactalbumin-oleic acid had a decrease of 89 percent in lesion volume from baseline, and in three of the four at least one lesion disappeared. In contrast, the five immunosuppressed patients in the placebo group had only a 12 percent decrease in lesion volume from baseline, but after open-label treatment with  $\alpha$ -lactalbumin-oleic acid, the volume of their lesions had decreased by 73 percent. At follow-up approximately two years later, 95 percent (39 of 41) of the lesions in the immunosuppressed patients had completely resolved (all immunosuppressed patients entered the open-label treatment phase).

#### DISCUSSION

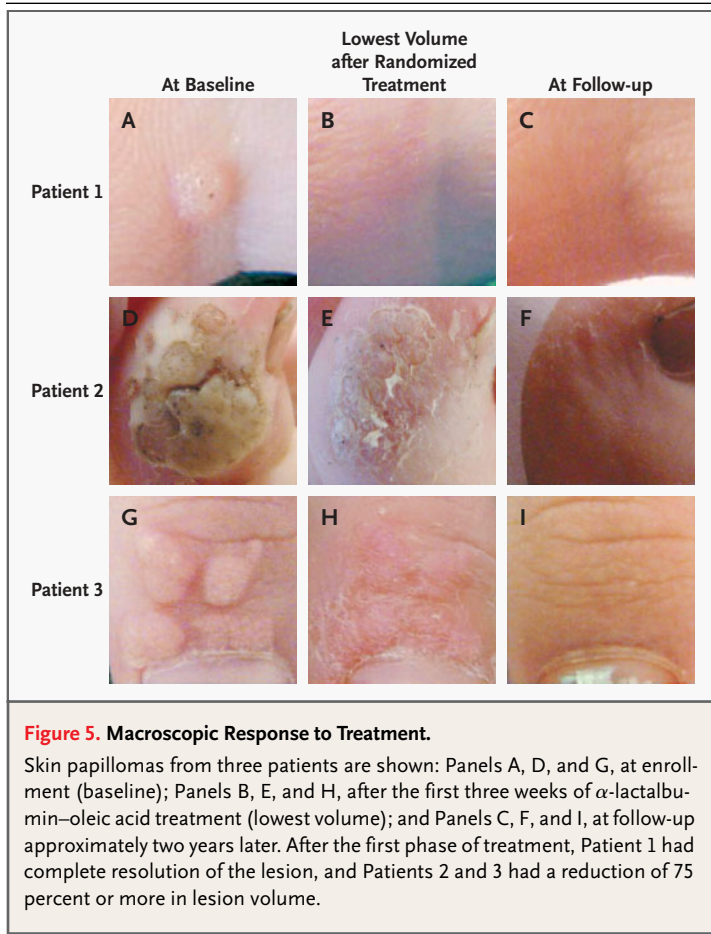
$\alpha$ -Lactalbumin-oleic acid is a protein-lipid complex that induces apoptosis-like death in transformed cells in vitro. In this study, designed as a proof of principle, we investigated the effect of



**Figure 4. Outcomes of Treatment According to Initial Treatment Assignment and Immune Status.**

The two-year follow-up data are based on the 21 patients who chose not to receive conventional treatment after the two phases of the study. Lesion-volume percentages are of the total lesion volume at baseline. Error bars indicate standard errors.

$\alpha$ -lactalbumin-oleic acid on skin papillomas. Forty patients and a total of 166 papillomas were treated according to a randomized, placebo-controlled protocol.  $\alpha$ -Lactalbumin-oleic acid reduced the lesion volume by at least 75 percent in all 20 patients assigned to this treatment and in 96 percent of the papillomas, as compared with 15 percent of pa-



tients and 20 percent of lesions in the placebo group ( $P < 0.001$ ). The lesions in the placebo group responded to subsequent treatment with  $\alpha$ -lactalbumin–oleic acid, with a median reduction in lesion volume of 82 percent. With time, all lesions resolved completely in most of the patients who received  $\alpha$ -lactalbumin–oleic acid (29 of 35 patients [83 percent]), and these patients were still free of lesions at the two-year follow-up. These results establish that  $\alpha$ -lactalbumin–oleic acid is active in humans.

In the past, the treatment of papillomas has had limited success. Salicylic acid has a cure rate of about 75 percent, as compared with 48 percent in placebo groups,<sup>11</sup> but in most studies, lesions persist despite rigorous treatment. Resistance to treatment is influenced by the HPV type and the viral load. We enrolled patients with lesions that were resistant to conventional therapies. The relatively low rate of spontaneous cure in the placebo group, compared with the rates in earlier studies, could re-

flect this selection factor. On the other hand, treatment with  $\alpha$ -lactalbumin–oleic acid was effective in most patients despite the prior failure of conventional therapies. After two three-week courses of  $\alpha$ -lactalbumin–oleic acid (one three-week course in the group that received placebo in the first phase of the study),  $\alpha$ -lactalbumin–oleic acid appeared to be at least as effective as conventional therapies.

This exploratory study of the therapeutic potential of  $\alpha$ -lactalbumin–oleic acid leaves a number of issues unresolved. Most important, the absorption of  $\alpha$ -lactalbumin–oleic acid through the stratum corneum of papillomas has not been studied. Distribution experiments in intact papillomas might be conducted with the use of laser-based techniques to trace fluorescently labeled  $\alpha$ -lactalbumin–oleic acid in intact lesions in vivo. However,  $\alpha$ -lactalbumin–oleic acid has been shown to penetrate through tumor-biopsy specimens and to diffuse throughout entire brain hemispheres after intracerebral delivery in rats.<sup>16</sup> It will also be essential to use biopsy material to investigate whether  $\alpha$ -lactalbumin–oleic acid penetrates papilloma tissue and induces apoptosis in vivo.

The effect of  $\alpha$ -lactalbumin–oleic acid on tumor cells and transformed cell lines was discovered by chance when a lung-cancer cell line was exposed to a human milk fraction obtained by low pH treatment.<sup>12</sup> After extensive purification, the activity was attributed to  $\alpha$ -lactalbumin in a partially unfolded conformation stabilized by a lipid cofactor that was identified as oleic acid (C18:1 $\Delta^9$ ).<sup>13</sup> By deliberate unfolding and addition of the fatty acid cofactor, our group was able to convert native  $\alpha$ -lactalbumin to  $\alpha$ -lactalbumin–oleic acid, and the complex was defined as a novel molecular entity, comprising these two components.<sup>13</sup> The results illustrate how proteins can adopt new functions by changing their conformation in response to new environments, which also supply the appropriate cofactors. The present study exemplifies the way in which such beneficial folding variants might be used to treat disease.

$\alpha$ -Lactalbumin–oleic acid activates several aspects of the cell-death machinery. In tumor cell lines, this complex crosses the cell membrane and moves through the cytoplasm to the nucleus, where it accumulates and disrupts the chromatin.<sup>17</sup> Such nuclear accumulation does not occur in healthy cells, which remain viable in the presence of  $\alpha$ -lactalbumin–oleic acid. Tumor cells release



cytochrome *c* and activate caspases in response to  $\alpha$ -lactalbumin-oleic acid,<sup>18,19</sup> but cell death does not appear to be regulated by the classic apoptosis pathways;  $\alpha$ -lactalbumin-oleic acid kills tumor cells in vitro, regardless of their p53 status, and cell lines with wild-type, null, or mutant p53 genotypes do not differ in susceptibility to  $\alpha$ -lactalbumin-oleic acid.<sup>14</sup> The effect of  $\alpha$ -lactalbumin-oleic acid on HPV-infected cells was therefore not unexpected. The *E6* and *E7* genes of HPV type 16 and type 18 have been shown to immortalize infected cells by inactivating p53, but this step should not influence the response to  $\alpha$ -lactalbumin-oleic acid.

Interestingly,  $\alpha$ -lactalbumin-oleic acid elevates the concentration of intracellular calcium ions,<sup>12</sup> and calcium-ion fluxes have been shown to stimulate terminal differentiation of keratinocytes.<sup>20</sup> We speculate that  $\alpha$ -lactalbumin-oleic acid may act both by inducing apoptosis-like death in rapidly proliferating cells and by turning on the differentiation program that is halted in the transformed keratinocytes in papillomas. Further experiments in keratinocytes are required to address these questions.

The effectiveness of  $\alpha$ -lactalbumin-oleic acid in the immunosuppressed patients in our study is important, since immunosuppression is known to increase susceptibility to many viral agents, including HPV.<sup>7-9</sup> Most people are infected by HPV during their lifetimes and may become carriers, but immunosuppressed patients tend to have lesions that are difficult to eradicate, and their treatment is a major problem. Papillomas develop in

90 percent of renal-transplant recipients, for example, within five years after transplantation.<sup>21</sup> The efficacy of  $\alpha$ -lactalbumin-oleic acid in immunosuppressed patients is consistent with the proposed mechanism of action, since the clearance of apoptotic cells is carried out by the innate defense system and does not require a specific immune response. Topical  $\alpha$ -lactalbumin-oleic acid might thus offer a substantial improvement in treatment for immunosuppressed patients with papillomas, who currently rely on laser therapy or other invasive methods.

$\alpha$ -Lactalbumin-oleic acid has unusual properties that enhance its potential as a new therapeutic agent. It is derived from human milk and thus is likely to be beneficial for breast-fed children. The protein used in this study was purified from milk that met the stringent criteria for feeding to premature babies. In a previous in vivo study of nude rats, xenotransplanted with human glioblastomas, no toxicity was observed,<sup>16</sup> and we did not record any side effects on the skin of the treated patients. Other unusual features of this complex are its apoptosis-like mechanism of action and its apparent selectivity for tumor cells and immature cells. We conclude that  $\alpha$ -lactalbumin-oleic acid has potential as a novel therapeutic tool in the treatment of papillomas and other tumors.

Supported by grants from the American Cancer Society, the Swedish Cancer Foundation, the Swedish Pediatric Cancer Foundation, the Medical Faculty of Lund University, the Segerfalk Foundation, and the Anna-Lisa and Sven-Eric Lundgren Foundation for Medical Research, Lund.

We are indebted to Camilla Svensson for help with the initial patients and to Lennart Philipson for valuable suggestions.

## REFERENCES

- zur Hausen H. Papillomaviruses and cancer: from basic studies to clinical application. *Nat Rev Cancer* 2002;2:342-50.
- Idem*. Papillomavirus infections — a major cause of human cancers. *Biochim Biophys Acta* 1996;1288:F55-F78.
- The world health report. Geneva: World Health Organization, 2003. (Accessed April 10, 2004, at <http://www3.who.int/whosis/menu.cfm>.)
- Strauss MJ, Shaw EW, Bunting H. Crystal-line virus like particles from skin papillomas characterized by intranuclear inclusion bodies. *Proc Soc Exp Biol Med* 1949;72:46-50.
- zur Hausen H, Meinhof W, Scheiber W, Bornkamm GW. Attempts to detect virus-specific DNA in human tumors. I. Nucleic acid hybridizations with complementary RNA of human wart virus. *Int J Cancer* 1974;13:650-6.
- de Villiers EM. Papillomavirus and HPV typing. *Clin Dermatol* 1997;15:199-206.
- Walder BK, Robertson MR, Jeremy D. Skin cancer and immunosuppression. *Lancet* 1971;2:1282-3.
- Bouwes Bavinck JN, Berkhout RJ. HPV infections and immunosuppression. *Clin Dermatol* 1997;15:427-37.
- Harwood CA, Surentheran T, McGregor JM, et al. Human papillomavirus infection and non-melanoma skin cancer in immunosuppressed and immunocompetent individuals. *J Med Virol* 2000;61:289-97.
- Leman JA, Benton EC. Verrucas: guidelines for management. *Am J Clin Dermatol* 2000;1:143-9.
- Gibbs S, Harvey I, Sterling J, Stark R. Local treatments for cutaneous warts: systematic review. *BMJ* 2002;325:461.
- Hakansson A, Zhivotovskiy B, Orrenius S, Sabharwal H, Svanborg C. Apoptosis induced by a human milk protein. *Proc Natl Acad Sci U S A* 1995;92:8064-8.
- Svensson M, Hakansson A, Mossberg AK, Linse S, Svanborg C. Conversion of alpha-lactalbumin to a protein inducing apoptosis. *Proc Natl Acad Sci U S A* 2000;97:4221-6.
- Svanborg C, Agerstam H, Aronson A, et al. HAMLET kills tumor cells by an apoptosis-like mechanism — cellular, molecular, and therapeutic aspects. *Adv Cancer Res* 2003;88:1-29.
- Lindahl L, Vogel HJ. Metal-ion-dependent hydrophobic-interaction chromatography of alpha-lactalbumins. *Anal Biochem* 1984;140:394-402.
- Fischer W, Gustafsson L, Mossberg AK, et al. Human alpha-lactalbumin made lethal to tumor cells (HAMLET) kills human

- glioblastoma cells in brain xenografts by an apoptosis-like mechanism and prolongs survival. *Cancer Res* 2004;64:2105-12.
17. Düringer C, Hamiche A, Gustafsson L, Kimura H, Svanborg C. HAMLET interacts with histones and chromatin in tumor cell nuclei. *J Biol Chem* 2003;278:42131-5.
18. Kohler C, Gogvadze V, Hakansson A, Svanborg C, Orrenius S, Zhivotovsky B. A folding variant of human alpha-lactalbumin induces mitochondrial permeability transition in isolated mitochondria. *Eur J Biochem* 2001;268:186-91.
19. Kohler C, Hakansson A, Svanborg C, Orrenius S, Zhivotovsky B. Protease activation in apoptosis induced by MAL. *Exp Cell Res* 1999;249:260-8.
20. Bikle DD, Tu CL, Xie Z, Oda Y. Vitamin D regulated keratinocyte differentiation: role of coactivators. *J Cell Biochem* 2003;88:290-5.
21. Leigh IM, Glover MT. Skin cancer and warts in immunosuppressed renal transplant recipients. *Recent Results Cancer Res* 1995;139:69-86.

Copyright © 2004 Massachusetts Medical Society.